

Endochondral Ossification (Part 3)

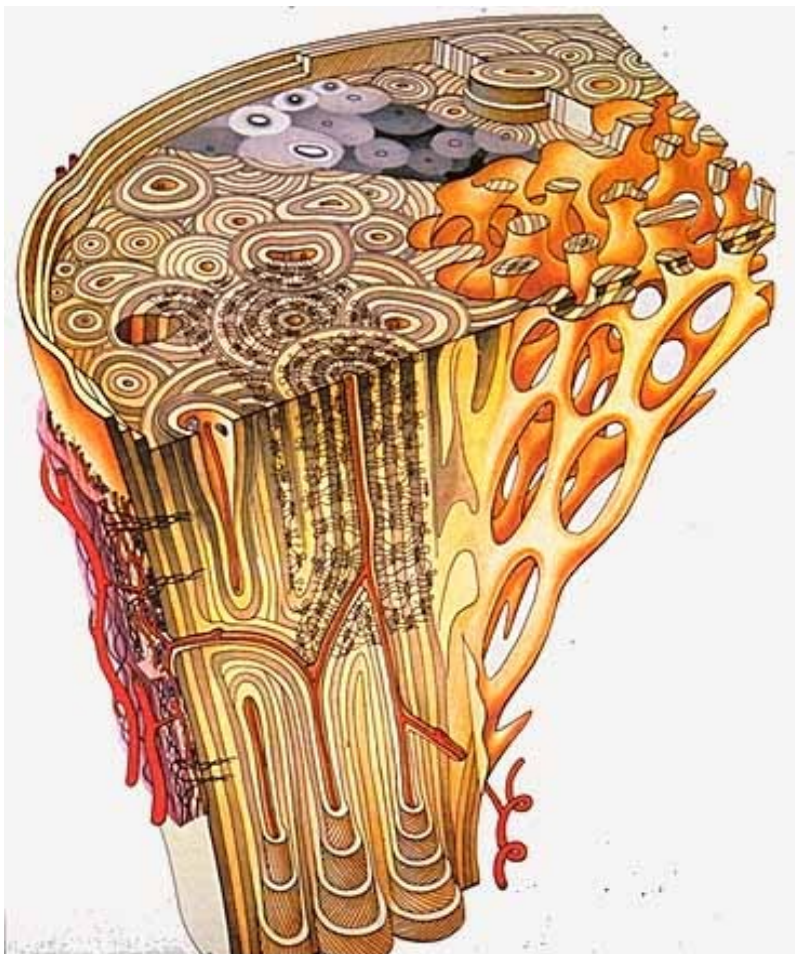
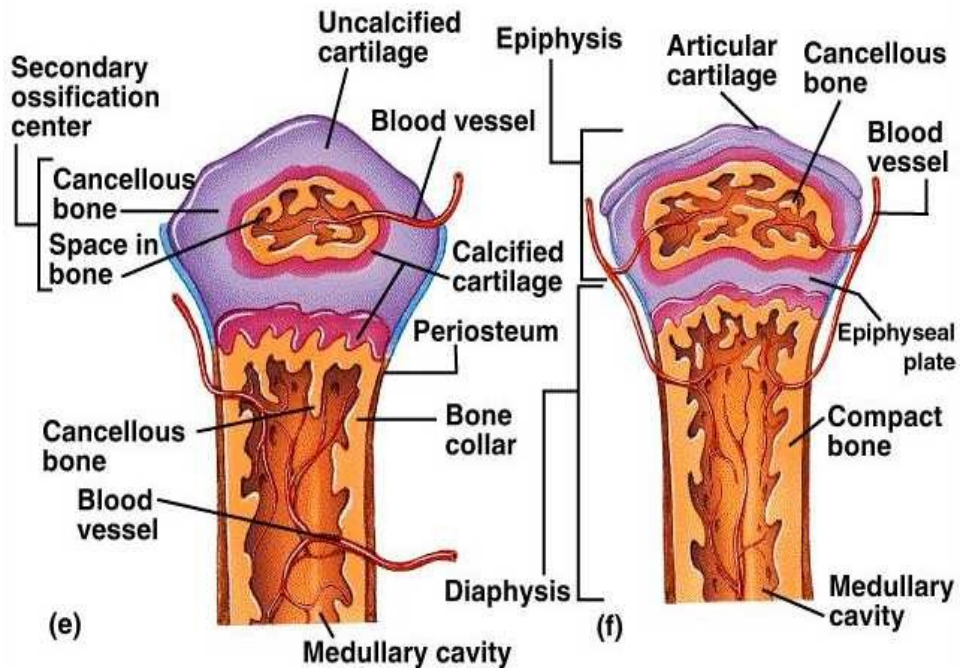
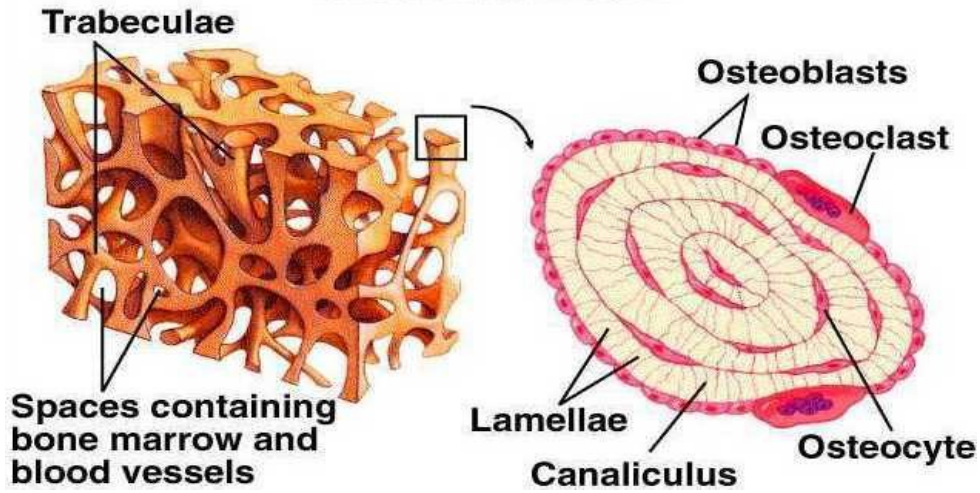


Figure 13. Structure of mature bone in both transverse and longitudinal section. Areas of compact and cancellous bone are also shown.

Cancellous Bone



Compact Bone

